

# Rachel Carson Center

## Perspectives

How to cite:

Kemp, Barry and Albert Zink. "Life in Ancient Egypt: Akhentanen, the Amarna Period, and Tutankhamun." In: "Sickness, Hunger, War, and Religion: Multidisciplinary Perspectives," edited by Michaela Harbeck, Kristin von Heyking, and Heiner Schwarzberg, *RCC Perspectives* 2012, no. 3, 9–23.

All issues of *RCC Perspectives* are available online. To view past issues, and to learn more about the Rachel Carson Center for Environment and Society, please visit [www.rachelcarsoncenter.de](http://www.rachelcarsoncenter.de).

Rachel Carson Center for Environment and Society  
Leopoldstrasse 11a, 80802 Munich, GERMANY

ISSN 2190-8087

© Copyright is held by the contributing authors.

SPONSORED BY THE



Federal Ministry  
of Education  
and Research

Deutsches Museum 



**Life in Ancient Egypt  
Akhentanen, the Amarna Period, and Tutankhamun**

Barry Kemp and Albert Zink

**Authors****Barry Kemp**

The McDonald Institute for Archaeological Research  
University of Cambridge  
Downing Street  
Cambridge CB2 3ER  
Great Britain

**Albert Zink**

EURAC Research  
Institute for Mummies and the Iceman  
Viale Druso 1  
39100 Bolzano  
Italy

Barry Kemp

### **An Unintended Social Experiment: Pharaoh Akhenaten at Amarna**

The royal mummies of the family that included Tutankhamun span a period of some fifty years that centers on the seventeen-year reign of Pharaoh Akhenaten (ca. 1351–1334 BC). The people who lived at the time experienced the effects of a religious revolution. Instigated by Akhenaten, it led to the rapid creation of a new capital city: the modern archaeological site of Tell el-Amarna. Simultaneously, the country seems to have been affected by an epidemic that spread into neighbouring countries, at least as far as the Hittite kingdom in Anatolia.

Akhenaten lived at a time of great prosperity and international exchanges, in which trade, diplomacy, and limited warfare were constants. It was Egypt's principal imperial age, celebrated at home with temple building on a large scale (much of Karnak and Luxor temples belong to this period, as do the "Colossi of Memnon," created for Akhenaten's father, Amenhotep III).

We know next to nothing about the influences that led Akhenaten to behave as he did. The sources give the impression of a man driven by a vision that dictated a course of action that was bound to lead to conflict. That vision was for the zealous purification of the one source of power that lay beyond human reach, yet was visible: namely, the sun and its light.

His purification took two forms. One was to ignore conventional theology and, in the case of the principal deviation from a purist's view of the sun—the human-shaped god Amun, who had partially absorbed the solar cult—to go on the attack and attempt to erase his existence. This Akhenaten pursued thoroughly (though his attack on the existence of other gods and goddesses was minor and inconsistent).

The other was to identify a place where the sun could be worshipped, uncontaminated by prior human or divine associations. As chosen by Akhenaten, this was a semicircle of desert on the east bank of the Nile, bounded by cliffs cut by wadi mouths that created a horizon line above which the sun rose clearly and dramatically. He called the place Akhetaten, "The Horizon of the Aten." It is the modern archaeological site

of Tell el-Amarna. We know something of what was in his mind from a first-person narrative recorded in a series of boundary texts carved into the faces of the cliffs. It includes his list of important constructions, comprising temples to the Aten, palaces and other places for the royal family, and tombs for them all and for those most closely associated with him (his “priests”).

Nothing is said about a city. He must have known, nonetheless, that many thousands of people would come to live there: junior officials, soldiers, people involved in manufacture, and even more whose place in life was to serve others. Although they were necessary, their needs fell outside his vision. They were left to build their own city, which they did rapidly and in a way that remains a remarkable witness to the power of self-organization. Perhaps as many as twenty or thirty thousand people found themselves making a home within a long, narrow city that had the river on one side, and empty desert on the other. They became the subjects (and in many cases the victims) of an experiment in community creation, which was an unintended by-product of Akhenaten’s determination to convert his vision into a large-scale reality.

To judge from the language that he used, he acted out of piety, a wish to re-establish the spiritual basis of Egypt on purer lines. It is likely that he instructed those around him to live more righteous lives, but it was not in his mind to create a popular movement of “Atenists” who would stand apart from unbelievers. This kind of division, which has been a striking characteristic of religion since Hellenistic times, still lay in the future.

This is the background to the following study made by Albert Zink and his colleagues, which looks at the identities of the mummies preserved on the site. The individuals who make up the group of mummies include Akhenaten himself (this identification is a major result of the research), his father (Amenhotep III) and grandparents (Yuya and Thuya), and his successor king-but-one, Tutankhamun (almost certainly a son), in whose reign Akhenaten’s experiment was brought to an end.

Since 2006, archaeological excavation at Amarna has begun to yield a parallel human population: the people of the city itself, who willingly or unwillingly bore the brunt of Akhenaten’s grand scheme. The site of the excavation is one of several cemeteries of Amarna’s people. We have called it the South Tombs Cemetery, because it lies behind one of the two groups of rock-cut tombs made for Akhenaten’s officials.

The cemetery had been robbed in ancient times and most of the burials disturbed. But careful recovery and recording is enabling a team of anthropologists from the University of Arkansas (led by Professor Jerry Rose) to reassemble skeletons, partially or wholly. As a result, we have a total of around two hundred individuals to work with, with a target of four hundred to aim for. A profile of their health is emerging that has several marked features. Inadequacy of diet in childhood showed itself in several ways, including retardation of body growth. Injuries were common, often spinal and produced by having to bear loads that were too heavy. An abnormal peak of deaths amongst people in their late teens and twenties is consistent with written sources from the eastern Mediterranean that speak of an epidemic.

The picture stands in marked contrast to the images of abundance which accompanied the cult of the Aten. The temples were designed to supply food on a large scale, but the system seems to have been inadequate. Perhaps it needed a longer time to settle down to being the city's main provider of food. The epidemic must have hindered its development.

Anthropology offers a new angle from which to view Akhenaten's reign, a source that is independent of the evidence we have previously relied on. It would be of great benefit if representatives of our citizen population could be examined in the same way that the royal mummies have been. Then we might better know to what extent kings and commoners shared some of life's experiences.

Albert Zink\*

### **King Tutankhamun and the Royal Family of the Eighteenth Dynasty of Ancient Egypt**

The genealogy of Tutankhamun is one of the greatest remaining unsolved mysteries in Egyptology (Carter and Mace 1927). For decades, experts all over the world have studied and debated the pharaoh's true lineage. However, due to the lack of concrete archaeological and Egyptological evidence, no conclusion was reached until now.

\* In collaboration with Zahi Hawass (Egyptian Supreme Council of Antiquities), Yehia Z. Gad (Egyptian National Research Center), Somaia Ismail (Central Hospital Bolzano), Paul Gostner (Kasr Al Ainy Faculty of Medicine), Ashraf Selim, and Carsten M. Pusch (University of Tübingen)

In 1922 Howard Carter uncovered the almost undisturbed tomb and the royal mummy of a nineteen-year-old boy from the late Eighteenth Dynasty, now popularly known as King Tut. This burial trove remains one of the most remarkable discoveries in Egyptology to date, capturing the public imagination in an unprecedented way, and Tutankhamun's life (and the causes of his premature death) 3,300 years ago continues to be a subject of fascination. However, despite the wealth of artifacts found, the tomb contained very little information about Tutankhamun's origins and family. Some names of key figures from the period appear amongst the artifacts, but no one inscription definitively tells us who the pharaoh's parents were. Furthermore, few other mummies from the Amarna period have been definitively identified. Many Egyptologists believe that Tutankhamun was born to the pharaoh Akhenaten and his great royal wife Nefertiti, or his second wife Kiya, but these claims are highly debated.

**Figure 1:**  
The mummified head of Tutankhamun, whose mummy is exhibited in Luxor, Egypt



Our study, which finally presents the real pedigree of the Eighteenth Dynasty royal family, constitutes a milestone in palaeogenetics (see Hawass et al. 2010). Using a multidisciplinary working model, we were able to identify and interpret nuclear DNA in a number of different royal mummies and put the existing hypotheses about their identities to the test.

This was facilitated by the preservation of nucleic acids in the corpses, which we speculate was a result of the particular (but as yet poorly understood) embalming techniques of the ancient priests. As these techniques reached their peak with the Eighteenth Dynasty, we were provided with DNA of extraordinary quantity and quality.

### **Previous Identifications**

On Tutankhamun's paternal side, most Egyptologists turn to the skeletonized mummy found in tomb KV55, widely considered to be that of Akhenaten (Baker 2008). There is a great deal of archaeological evidence to support this claim, although previous anthropological studies identified the mummy as a man in his early twenties, leading to the hypothesis that he could be the enigmatic pharaoh Smenkhkare (Harrison 1966). Little is known about Smenkhkare, other than that he seems to have ruled for a brief period around the time of Akhenaten's death. In either case, this mysterious KV55 mummy is a good candidate to be Tutankhamun's father.

The mother of Tutankhamun may be one of the two female mummies found in tomb KV35 in the Valley of the Kings, Luxor. These two mummies were named according to their different ages at death: the Younger Lady and the Elder Lady (Harris and Wente 1980). Besides the style of their mummification, which is consistent with royal females of the Eighteenth Dynasty, there is no clear evidence about the identity of these mummies. However, the Younger Lady mummy has been claimed at times to be Nefertiti or Kiya, either of Akhenaten's two wives, which makes her a prime subject to be Tutankhamun's mother. Some scholars also believed that the beautifully preserved Elder Lady may be the mummy of Nefertiti, or of Queen Tiye, the royal wife of the long ruling pharaoh Amenhotep III and the mother of Akhenaten.

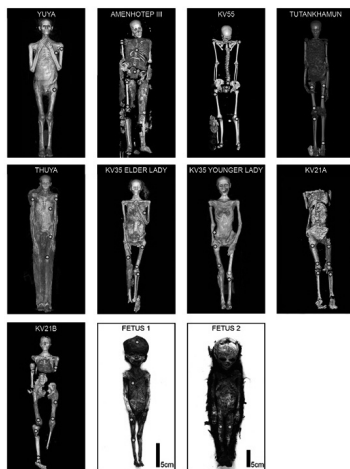
Apart from Tutankhamun himself, the only mummies whose identities are known with complete certainty, and are known to be members of Tutankhamun's family group, are the mummies of his putative paternal great-grandparents, Thuya and Yuya. These two nobles were also found in an almost undisturbed tomb in the Valley of the Kings, clearly identified, and provide a good control group for genetic analyses. To further investigate Tutankhamun's family tree, the two fetuses found in his tomb—possibly his offspring—were also examined, as well as the two female mummies from the tomb of KV21, either of whom might be his wife.



## Material and Methods

Eleven mummies of the Eighteenth Dynasty (ca. 1550–1295 BCE) of the New Kingdom (ca. 1570–1070 BCE) underwent a detailed anthropological and radiological study in order to determine the preservation status, the individual's age and sex, and also to reveal any evidence of disease or the cause of death. For the radiological analysis, the mummies were scanned using a multidetector CT unit “emotion 6” by Siemens Medical Systems. This information was further used to identify the exact locations to take tissue samples for later DNA extraction in the laboratories.

**Figure 2:** Compilation of full-body images of the examined Eighteenth Dynasty mummies. All mummies are shown as 3D VRT-CT images, except for the fetuses, which are photographic images. Names of the individuals or tomb are indicated.



Subsequently, the mummies were sampled by taking small bone punch biopsies from at least four different areas of the corpse. The samples were stored in sterile tubes and transferred to dedicated ancient DNA laboratories for further processing. The ancient DNA extractions of the bone samples and all further analytical steps, such as polymerase chain reaction (PCR) amplification, cloning, and sequencing, were all performed following strict and widely accepted guidelines (Richards, Sykes, and Hedges 1995). Along with these precautions, detailed contamination monitoring protocols for the PCR experiments were included in the research (mock and negative controls, separate working areas, etc.). Moreover, all involved lab members were tested for their Y-chromosomal and autosomal markers. For authentication of the results, all analytical steps were repeated at least five times; in addition, a subset of the data was independently replicated in a newly equipped lab exclusively dedicated to ancient DNA work.

The analyses of the ancient Egyptian mummy samples included laborious optimization strategies by applying several different DNA extraction and purification protocols. Inhibition PCR experiments were performed in a third lab, located at the National Research Center, Cairo, to titrate for the proper amount of amplifiable ancient DNA. After the successful extraction of DNA, we performed an intensive genetic testing of nuclear DNA loci including sixteen Y-chromosomal (AMPFLSTR Yfiler PCR Amplification kit,

Applied Biosystems) as well as eight autosomal microsatellite markers (AMPFLSTR Minfiler PCR Amplification kit, Applied Biosystems).

## Results and Discussion

### *Kinship Analyses*

The optimization protocols for extraction and purification of DNA, PCR amplification, sequencing and fragment length analyses yielded results for all mummies under investigation. The genetic data clearly identified the mummies of KV35 Elder Lady, and KV55. Our results, in conjunction with archaeological data, provide substantial evidence that the mummy found in KV55 is indeed Akhenaten, and that the KV35 Elder Lady is Tutankhamun's paternal grandmother, Queen Tiye. Moreover, the KV55 mummy and the KV35 Younger Lady mummy can safely be identified as the father and mother of Tutankhamun. This is demonstrated by the following results:

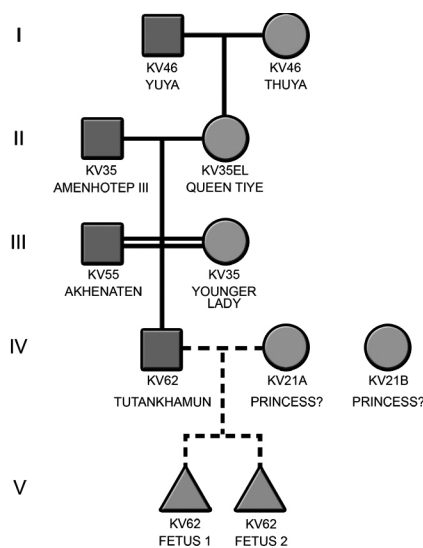
	Alleles deriving from Amenhotep III			Alleles deriving from Yuya			Alleles deriving from Thuya		
Marker	1	2	3	4	5	6	7	8	
Mummy	D13S317	D7S820	D2S1338	D21S11	D16S539	D18S51	CSF1PO	FGA	
TY	9	12	10	13	19	26	26	35	
YU	11	13	6	15	22	27	29	34	
EL*	11	12	10	15	22	26	26	28	
AM	10	16	6	15	16	27	25	34	
KV55*	10	12	15	15	16	26	29	34	
YL*	10	12	6	10	16	26	25	20	
KT*	10	12	10	15	16	26	29	34	
KV21A	10	16	NDO	NDO	NDO	28	NDO	35	
KV21B	10	NDO	NDO	NDO	17	26	NDO	NDO	
F1	12	16	10	13	16	NDO	29	NDO	
F2	10	NDO	6	15	NDO	26	29	35	

Figure 3:

Microsatellite data of mummies thought to belong to the Tutankhamun kindred. Segregation of alleles is indicated by color. Note that data replication for Tutankhamun, Elder Lady, Younger Lady, and KV55 was successfully performed in the second Cairo laboratory (\*). KT, Tutankhamun; AM, Amenhotep III; KV55, Akhenaten; F1, fetus 1; F2, fetus 2; KV21A; KV21B; TY, Thuya; YU, Yuya; EL, Elder Lady; YL, Younger Lady. "NDO" is abbreviated for "no data obtained." All established genotypes differ from those of the lab staff.

1. The established Y-chromosomal profiles show identical patterns in Amenhotep III, KV55, and Tutankhamun. This provides evidence that these individuals share the same paternal lineage. Control mummies examined along with Tutankhamun's putative family members yielded different Y-specific alleles.

2. Fine analysis of the genetic relationship between the mummies was achieved by a genetic fingerprint typing exploring autosomal alleles. We obtained complete fingerprint profiles of all individuals except for one of the KV62 fetuses and both mummies from KV21, who yielded partial data sets. By evaluating the segregation of alleles through the generations, we reconstructed the most plausible royal pedigree: a five-generation family tree.



**Figure 4:**  
Pedigree showing the genetic relationships of the tested Eighteenth Dynasty mummies. Quadrants define males, circles illustrate females, and triangles stand for still-birth. A double line represents an interfamilial marriage (here it is a first degree brother-sister relationship). Dotted lines indicate insufficient data; thus, the relationship is meant to be a proposal. Note that fetus 1 and fetus 2 could be daughters of Tutankhamun; however, the mother is not known to date. The few data obtained from KV21A are not enough to identify her as Ankhesenamun, wife of the boy pharaoh.

- Yuya and Thuya are the parents of the KV35 Elder Lady, indicating that she is most likely Queen Tiye, the royal wife of Amenhotep III.
- Both Amenhotep III and the now identified Queen Tiye are the parents of the mummy found in KV55 and also the Younger Lady found in KV35.
- Anthropological and radiological analysis of the KV55 mummy showed that he was much older than previously assumed, which provided evidence that this mummy could be the pharaoh Akhenaten, and not Smenkhkare. Further support for this claim was found on the sarcophagus of KV55: gold sheets that were once attached to the lid of the coffin identify the pharaoh Akhenaten, sun god. The proof that Amenhotep III and Queen Tiye are the parents of KV55, combined with this anthropological and archaeological evidence, clearly indicates that the mummy in KV55 is Akhenaten.

- The KV35 Younger Lady could be Nefertiti or Kiya, or possibly one of Akhenaten's sisters, who would have been the right age to give birth to Tutankhamun. Specifically, we should also mention the eldest sister of Akhenaten, Sitamun, as a possible identity for KV35 Younger Lady. Daughter of Amenhotep III and Queen Tiye, Sitamun was the most well-known of their offspring, and could also be Tutankhamun's mother.
- Subsequently, Akhenaten and KV35 Younger Lady are the parents of Tutankhamun.
- Additionally, Tutankhamun might be the father of at least one of the fetuses found in KV62.

### *Gynecomastia and Syndromes*

The most prominent feature of the Amarna portrayals of Akhenaten—and, to a lesser degree, Tutankhamun—is their feminine appearance in some busts and statuettes. Disregarding artistic considerations, this might reasonably suggest some form of gynecomastia, abnormal breast enlargement in the male, as an underlying disease (Paulshock 1980).



**Figure 5:** Examples of El Amarna art (ca. 1351–1334 BC) showing Akhenaten. JE49528, colossus statue that once lined a colonnade in the Precinct of the Aten at Karnak temple, Eighteenth Dynasty, reign of Akhenaten (left).

JE49529, colossus of Akhenaten, Karnak, Precinct of the Aten, 18th Dynasty, reign of Akhenaten. The king wears a pleated kilt that hangs low on a swollen belly, and a double crown symbolizing dominion over Upper and Lower Egypt (right).

However, it is impossible to examine the mummies of Tutankhamun and Akhenaten (KV55) for putative breasts. KV55 is a mummified skeleton with no soft tissue remains, and Tutankhamun is missing the entire frontal chest wall, including ribs. Although Tutankhamun's pelvic bones are absent, KV55's pelvis is present but fragmented. It does not show any feminine features. We therefore cannot support the diagnosis of any form of gynecomastia or femininity.

It has also been suggested that Akhenaten and other family members may have suffered from Marfan syndrome (Braverman, Redford, and Mackowiak 2009). One criterion is

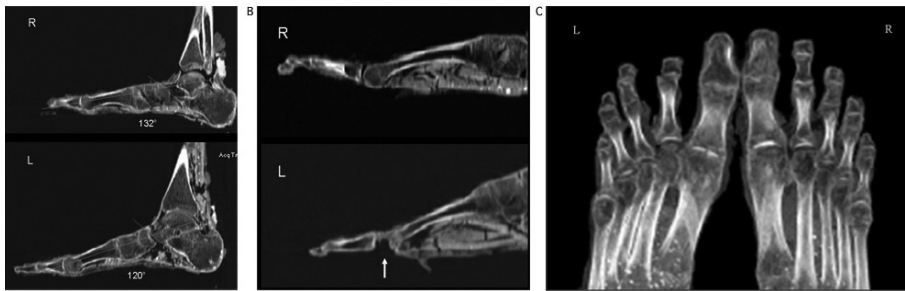
the presence of dolichocephaly, that is an abnormally long head (Pyeritz and McKusick 1979). We tested for this by establishing the cephalic indices for 15 mummies. Many scholars believe that dolichocephaly is present in individual members of the Eighteenth Dynasty. Dolichocephaly is frequently seen in busts and statuettes of the Amarna period (Nefertiti, Akhenaten and Tutankhamun are prominent examples). Technically, dolichocephaly is defined as a skull with a cephalic index (CI) of 75 or less. Apart from Yuya (CI = 70.3), no mummies from the Tutankhamun lineage satisfy the criterion. However, Akhenaten's CI is 81.0 and Tutankhamun's 83.9, which defines their skulls as brachycephalic, or abnormally wide.

The diagnosis of Marfan syndrome is based on a combination of the major and minor clinical features (De Paepe et al. 1996). The presence of either two major features or one minor feature, or of one major feature and four minor features, supports a diagnosis of Marfan syndrome. Following this classification, we could not find evidence to add weight to a Marfan diagnosis.

#### *Radiological Findings*

Previous X-ray analyses have revealed much about the life of the pharaoh; however, they have also left plenty of questions unanswered over the years. Our study was designed either to confirm or refute the conclusions of previous examinations, and it focused on details that earlier studies might have overlooked. We specifically looked for life-threatening elements that might have directly caused the king's death, or been linked to his cause of death. While our inspection of the rest of his body did not result in any new information, a detailed examination of his feet was revealing. The arch of his right foot is low (angle after Rocher: 132°, normal value 126°); there are no pathological findings on the bone structure of the right foot. The tarsal, metatarsal, and phalanges are completely preserved.

The left foot has a slightly higher-than-normal arch (angle after Rocher: 120°). The fore-foot is supine and inwardly rotated in a position suggesting equinovarus deformity (club foot). Despite significant bone degradation, the structure of the second metatarsal head is visibly altered, with areas of both increased and decreased bone density. There is a crater-shaped bone and a soft-tissue defect on the plantar surface. Furthermore, the metatarso-phalangeal joint space is widened. The articulating surface of the phalange



**Figure 6:** Feet pathology in Tutankhamun.


A) Axial CT cross section with sagittal CT reconstruction of the feet. The right foot arch is flat compared to the left, displaying features of a flat foot.

B) Axial CT reconstruction of the second metatarsal of the right and left feet: The second metatarsal bone head shows evidence of bone destruction with loss of bone substance and soft tissue. The second toe of the left foot lacks the second phalanx (oligodactyly). The right foot is without pathological findings.

C) CT reconstruction of both forefeet: The right foot shows no pathological findings. The second toe of the left foot misses the second phalanx (oligodactyly). This toe is anteriorly displaced. The ungual phalanx is subluxated, the first toe is splayed. The bone necrosis of the second metatarsal head can be unambiguously identified.

is normal. The third metatarsal head is only slightly deformed, but its structure shows signs of apparent bone necrosis. The remaining metatarsal heads of the left foot appear normal; the second and third toes are in abduction. The second toe is shortened, because it lacks a second phalanx; the first phalanx joins directly with the ungual phalanx. These findings show that Tutankhamun suffered from a juvenile aseptic bone necrosis of the second and third metatarsal bones of his left foot (Köhler's disease II, Freiberg-Köhler syndrome). The widened joint space and the secondary changes to the second and third metatarsal heads indicate that the disease was still flourishing. Bone and soft tissue loss at the second metatarsophalangeal joint could further indicate an acute inflammatory condition resulting from ulcerative osteoarthritis and osteomyelitis.

There is concrete evidence that the pharaoh may have had this impairment for quite some time. Using a cane can considerably ease the impairment in walking caused by the syndrome. Howard Carter found 130 sticks and staves—counting whole and partial examples—in Tutankhamun's tomb. An inscription on one staff records that the king himself cut it from a bed of reeds while visiting a temple.



**Figure 7:** Private illustration showing the king essentially resting upon a cane while he is accompanied by his wife Ankhesenamun. Relief in KV62.

### *Infectious Diseases*

As the various macroscopic inspections, X-rays, and CT examinations conducted in the past did not yield any conclusive data, we considered various life-threatening diseases as potential causes of death. In order to test for the malaria-causing parasite *Plasmodium falciparum*, DNA PCR primers were designed that specifically amplify small *Stevor*, *Ama1*, and *Msp1* gene fragments, thereby yielding amplicons in the range of circa 100–250 bp. PCR products and cloned DNA fragments were sequenced. We identified *Plasmodium falciparum* DNA in the mummies of Tutankhamun, Yuya, and Thuya. Since we applied primers that are highly specific for the *P. falciparum* genome, we can safely conclude that our positively typed mummies suffered from *malaria tropica*, the most severe form of malaria.

### *Cause of Death*

Tutankhamun suffered from multiple physical disorders, and it is possible that some of them may have cumulated in an inflammatory, immunosuppressive syndrome, which would seriously undermine his health. We can imagine a young, frail king, who walked with a cane due to Köhler's Disease II (osteonecrotic and sometimes painful) together with oligodactyly in the right foot and club foot in the left. A sudden leg fracture, perhaps from a fall, would be life-threatening when combined with a *malaria tropica* infection.

### **Conclusions**

This multidisciplinary study (incorporating genetic, archaeological, anthropological, and Egyptological research) is the first concretely to clarify the lineage of Tutankhamun. As most of the archaeological and Egyptological data are still subject to debate, we established thorough genetic fingerprints of King Tutankhamun and his putative family members. By conducting a detailed ancient DNA study, we identified the mummies' origins and shed light on the pharaoh's family bonds.

## References

- Baker, Darrell. 2008. *Encyclopedia of the Pharaohs, Volume I: Predynastic to the Twentieth Dynasty*. Cairo: American University in Cairo Press.
- Braverman, Irvin M., Donald B. Redford, and Philip A. Mackowiak. 2009. "Akhenaten and the Strange Physiques of Egypt's 18th Dynasty." *Annals of Internal Medicine* 150 (8): 556–60.
- Carter, Howard and Arthur C. Mace. 1927. *The Tomb of Tut-Ankh-amun*. Vol. 2. London: Cassell and Co.
- De Paepe, Anne, Richard B. Devereux, Harry C. Dietz, Raoul C. Hennekam, and Reed E. Pyeritz. 1996. "Revised Diagnostic Criteria for the Marfan Syndrome." *American Journal of Medical Genetics* 62 (4): 417–26.
- Harris, James E. and Eduard F. Wente. 1980. *An X-Ray Atlas of the Royal Mummies*. Chicago: University of Chicago Press.
- Harrison, Ronald G. 1966. "An Anatomical Examination of the Pharaonic Remains Purported to Be Akhenaten." *Journal of Egyptian Archaeology* 52: 95–119.
- Hawass, Zahi, Yehia Z. Gad, Somaia Ismail, Rabab Khairat, Dina Fathallah, Naglaa Hasan, Amal Ahmed, Hisham Elleithy, Markus Ball, Fawzi Gaballah, Sally Wasef, Mohamed Fateen, Hany Amer, Paul Gostner, Ashraf Selim, Albert Zink, and Carsten M. Pusch. 2010. "Ancestry, Pathology and Cause of Death in King Tutankhamun's Family." *Journal of the American Medical Association* 303: 638–47.
- Paulshock, Bernadine Z. 1980. "Tutankhamun and His Brothers: Familial Gynecomastia in the Eighteenth Dynasty." *Journal of the American Medical Association* 244 (2): 160–64.
- Pyeritz, Reed E. and Victor A. McKusick. 1979. "The Marfan Syndrome: Diagnosis and Management." *New England Journal of Medicine* 300 (14): 772–77.
- Richards, Martin B., Bryan C. Sykes, and Robert E. M. Hedges. 1995. "Authenticating DNA Extracted from Ancient Skeletal Remains." *Journal of Archaeological Science* 22 (2): 291–99.